PROCEEDINGS

30th annual meeting of the

INTERNATIONAL ELBOW WORKING GROUP

June 23th 2016
FECAVA-VÖK Eurocongress, Hofburg
Vienna, Austria.

WELCOME ADDRESS

Vienna, June 23, 2016

Dear participants,

The board of the International Elbow Working Group (IEWG) is grateful to the organisers of the 22nd EuroCongress of the Federation of European Companion Animal Veterinary Associations (FECAVA) and the organizers of the 31st annual conference of the "Vereinigung Österreichischer Kleintiermediziner - VÖK" - for the hospitality offered, to organise a whole day programme dedicated to elbow dysplasias (ED). The IEWG has been founded in 1989 by a group of veterinarians and dog breeders with a concern about ED. The purpose of the IEWG is to gather and exchange knowledge and experiences about elbow diseases regarding hereditary aspects, aetiology, diagnosis, and prevention as well as screening of elbows of dogs. The latter includes a standardised method of radiology, radiological film reading, scoring the presence of the primary lesion and/or secondary osteoarthrosis as well as the use of a standardized scoring form. All the aspects of concern of the IEWG are directed to diminish the incidence of the developmental disturbances of the elbow joint in growing dogs of an increasing amount of dog breeds, with a great impact on the quality of life for both the patient and its owner. Therefore the World Small Animal Veterinary Association (WSAVA) recognised the IEWG as an affiliated group.
The IEWG can only accomplish this goal with the help of several experts who accepted the invitation to give an update in their field of expertise, and by the organisers of the congress of the FECAVA-VÖK congress to provide facilities in the congress programme. We are very grateful to Dr. Von Pückler and Dr. Ondreka from University of Giessen, and Dr Ohlert from the University of Zürich that they were found willing to share during the IEWG-seminar their knowledge and expertise in radiological screening for elbow dysplasia, including the IEWG-grading system as widely in use. These contributions are programmed as lectures as well as an interactive film-reading session, allowing the participant to gain more experience in judging the elbow joints and use the IEWG-grading system.

We are looking forward to an interesting scientific meeting. Since the IEWG meeting is open to all veterinarians, both present at the FECAVA2016-VÖK congress as those visiting us at the web page (http://www.vet-iewg.org/), we are assured of a large group of interested veterinarians to be informed about the current state of hereditary and clinical aspects of elbow dysplasia, the imaging techniques and IEWG-protocols, and the IEWG-grading system. We wish all participants a fruitful seminar,

Dr. H.A.W. Hazewinkel President	Dr. K.L. How Secretary	Dr. B. Telhelm Treasurer

International Elbow Working Group Annual Meeting

FECAVA Eurocongress/VÖK Jahrestagung,
June 23th 2016,
Hofburg, Vienna, Austria.

Chairperson: Prof. Dr. H.A.W. Hazewinkel

09.000 – 09.15	Welcome Prof. Dr. H.A.W. Hazewinkel
09.15 – 10.00	Clinical signs of Elbow Dysplasia and Osteoarthritis Dr. K.L. How
10.00 – 10.45	Mode of inheritance of Elbow Dysplasia and principles of screening methods Prof. Dr. H.A.W. Hazewinkel
10.45 – 11.00	Break
11.00 – 11.45	Explanation of the IEWG grading system Dr. S. Ohlerth
11.45 – 12.30	Case examples Dr. S. Ohlerth
12.30 – 14.00	Lunch
14.00 – 14.45	Elbow Dysplasia: Computed tomograph standards, protocols and quality assurance Dr. K.H. von Pückler
14.45 – 15.30	CT based assessment of ED: Proposal for a grading scheme Dr. N. Ondreka Film reading: Discussion of ED cases Dr. S. Ohlerth
15.30 – 16.00	Break
16.00 – 17.30	All participants are encouraged to contribute with their own cases Dr. N. Ondreka & Dr. K.H. von Pückler

List of speakers

Dr. H.A.W. Hazewinkel, Prof. em., DVM, PhD, Dipl. ECVS & ECVCN,
Department of Clinical Sciences of Companion Animals,
Faculty of Veterinary Medicine, Utrecht University,
PO box 80.154, 3508 TD Utrecht, The Netherlands,
h.a.w.hazewinkel@uu.nl.

Dr. K.L. How, DVM, NACAM Specialist in SA Surgery,
DSC Den Haag,
Regentesselaan 190, 2562 EH Den Haag, The Netherlands
how@wxs.nl

Dr. S. Ohlerth, PD Dr. med. vet., Dipl. ECVDI
Clinic for Diagnostic Imaging
Vetsuisse Faculty, University of Zurich
Winterthurerstrasse 258c, 8057 Zurich, Switzerland
sohlerth@vetclinics.uzh.ch

Dr. N. Ondreka, Dr. Med Vet., Dipl ECVDI,
Justus-Liebig- Universität Giessen,
Klinik fűr Kleintiere-Chirurgie,
Frankfurterstrasse 108, D-35392 Giessen, Germany,
Nele.Ondreka@vetmed.uni-giessen.de

Dr. K.H. von Pückler, Dr. Med Vet., Dipl ECVDI,
Justus-Liebig- Universität Giessen,
Klinik fűr Kleintiere-Chirurgie,
Frankfurterstrasse 108, D-35392 Giessen, Germany,
Kerstin.H.Pueckler@vetmed.uni-giessen.de

Clinical signs of Elbow Dysplasia and Osteoarthritis

K.L. How, DVM, NACAM Specialist in SA Surgery,

Front leg lameness in young large and giant breed dogs is most often caused by Elbow Dysplasia [ED]. Elbow Dysplasia is a multifactorial disease process with a genetic predisposition and secondary environmental influences. These influences include overnutrition, rapid growth, excessive exercise, and hormonal influences. There are 4 diseases that are grouped under the umbrella name of Elbow Dysplasia; ununited anconeal process [UAP], osteochondritis dissecans [OCD], medial coronoid disease [MCD] and elbow incongruity [INC]. In case of an UAP the anconeal process is not fused with the ulna at 16-20 weeks of age. OCD of the medial humeral condyle develops as a dislodged cartilage flap due to a disturbed enchondral ossification. MCD is the most frequent diagnosed form of ED and consists of pathologic changes of the articular cartilage and subchondral bone of the medial coronoid process. These conditions can be due to or get worsened by incongruity of the elbow joint [INC]. This INC can be caused by a relative short radius, a relative short ulna or relative oval shape of the trohlear notch. Elbow Dysplasia can effect one or both frontlegs and several forms of ED can be present in one leg.

Orthopedic examination

In the history of a patient with front leg lameness breed, gender, age of onset, and moment of lameness is important. Many large and giant breed dogs are affected with ED. UAP is more frequently diagnosed in German Sheppard Dogs. UAP and INC are also found in chondrodystrophic breeds. In Labradors, male dogs are affected twice as frequent as females, wheras in other breeds (e.g. Bernese Mountain dogs) there is no gender predilection for ED. Lameness becomes apparent from 5 – 7 months of age and starts oftentimes with inactivity stiffness in the morning or after resting.

During the history taking a first impression of the stance and locomotion can be obtained by watching the dog in the consultation room. Gait analysis can be done next by walking and trotting the dog outside on the leash. Home movies made by the owners, can also be very helpfull in cases where the dog doesn't show the lameness in a unfamiliar environment.

During walking the dog will favour the best leg by putting more weight on it. The leg with the effected elbow will be circumducted laterally during the swing phase of the gait. The animal may sit or stand with the paw externally rotated. In about one third of the cases the problem is bothsided and therefor limping may not always be vary obvious. In bothsided cases the dog may shift weight from one side to another during standing. Walking can be with a short and stiff stride, with more weight put on the hindlegs.

On physical examination both legs should be examined and muscle atrofie and soft tissue swelling evaluated. Elbow joint swelling can be palpated in the standing dog between the lateral humeral epicondyle and the olecranon. Also periarticular joint swelling can be palpable in more severe cases.

The elbow joint can have a smaler range of motion and pain can be elected by

hyperextension of the elbow with lateral rotation [supination]. Crepitation during passive motion can be felt in advanced cases of arthrosis.
To avoid misinterpretations, attention must be paid not to flex or bend the shoulder while manipulating the elbow. Possible problems in the shoulder joint, (OCD of the proximal humerus and tendinitis of the biceps muscle), but also enostosis of the long bones and trauma of the bones and ligaments of the elbow must be rouled out.

Diagnostic Imaging

The International Elbow Working Group advises 4 radiographic projections for an optimal radiographic evaluation of the elbow joint; craniocaudal [CrCd],craniolateral-caudomedial oblique [CrL-CdMO], 90° flexed mediolateral [ML] and extended 15°supinated mediolateral.
The UAP can be seen on a flexed mediolateral (ML) projection. OCD is seen as a triangular subchondral defect on the medial aspect of the humeral condyle in the craniocaudal (CrCd) or CrCdMLoblique projection. Oftentimes sclerosis of the medial condyle is present. OCD can be mistaken for a “kissing” leasions of a fragmented coronoid process (FCP). In case of medial coronoid disease [MCD] it is unlikely to find the primary lesion on radiographs. The presence of secondary degenerative joint changes are more likely to be found and are suggestive of MCD. Normal radiographs however don’t rule out MCD. Elbow joint congruity is best assessed on a 90 degrees flexed ML projection. Mild radioulnar incongruity cannot be reliably established based on radiographs.
Computed tomography [CT] is an excellent method to evaluate the elbow joint. Both elbows and shoulders can be examinedduring the same investigation. On the CT periarticular osteophytosis, contour and structure of all components of the elbow and radi0- ulnar incongruenty [INC] can be evaluated without disturbance of superimposed anatomy. Bone cysts can be seen in the ulna boardering the radio-ulnar joint. At the CT scan, especially the subchondral bone of the coronoid proces scan be inspected. However, MCD with fragments in situ or with minimally displaced fragments are sometimes difficult to detect on CT.
Arthroscopy gives visibility of all intra-articular joint structures, including the joint cartilagee covering the medial coronoid process, and allows for simultaneous minimal invasive treatment. Congruity can best be evaluated with the elbow in a neutral position and a angle of approximately 135 degrees.
Bone scintigraphy using technetium 99m linked to methylene diphosphonate can be used in cases of obscure frontleg lameness. Also in cases of multiple arthrotic joints in one leg a distinction can be made in the severity of arthrotic reaction of the involved joints. Bone scintigraphy is not suitable in immature dogs due to their active groth plates and its use is under strict radiation laws.

Management of ED

Elbow Dysplasia will inevitably lead to osteoarthritis of the elbow joint. Owner education is very important in the understanding of the disease process and that treament is not a curative procedure, but is to improve the joint function and slow down the degenerative joint disease.
The management of ED consists of surgical and medical therapy and optimising joint function with exercise modifications, weight management and medical support. The Nonsteroidal Anti-Inflammatory Drugs [NSAID’s] are the main drugs

used in osteoarthritis and can be given for longer periods of time. Side effects involving the gastrointestinal tract, platelets and kidneys must be monitored in cases of long term administration. Corticosteroids are very strong anti-inflammatory drugs, but are not used routinely because of the risk of cartilage damage and progressive joint destruction.
Platelet-rich plasma, stem cell therapy, hyaluronic acid, polysulfated glucosaminoglycan, chondroitin sulfate and glucosamine sulfate/hydrochloride are used frequently, but evidence is not always sufficient for their recommendation for routine use in dogs. Omega-3 fatty acids have been proven to have anti-inflammatory effects in dogs and are available as a supplement or added in commercial diets.
The majority of dogs with ED functions good to exellent. The degenerative joint disease however doesn't always respond as expected, leading to a severe degeneration of the medial compartment of the elbow joint, known as the Medial Compartment Disease. In cases with severe lameness corrective techniques, joint replacement, arthrodesis or salvage procedures remain as treatment options.

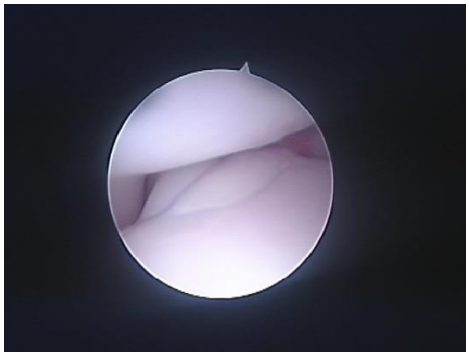

Fig 1. Medial Coronoid Disease
normal cartilage

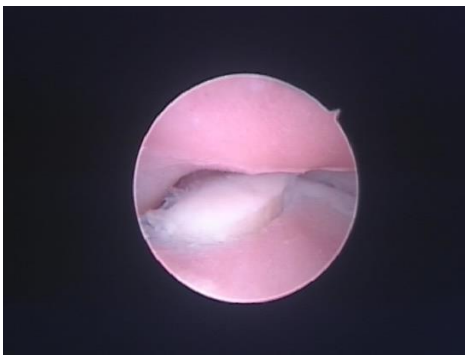

Fig 2. Medial Compartment Disease
full thickness cartilage loss

Suggested reading

S.F. Lau, L.F.H.Theyse, G.Voorhout, H.A.W. Hazewinkel: Radiographic, Computed Tomographic and Arthroscopic Findings in Labrador Retrievers With Medial Coronoid Disease. Vet. Surgery 44 [2015]: 511-520.
N. Fitzpatrick, T.J. Smith, R.B. Evens, R. Yeadon:Radiographic and Arthroscopic Findings in the Elbow Joints of 263 Dogs with Medial Coronoid Disease. Vet. Surgery 38 [2009]: 213-223.
J.P. Punke, D.A. Hulse, S.C. Kerwin, L.E. Peycke: Arthroscopic Documentation of Elbow Cartilage Pathology in Dogs with Clinical Lameness without Changes on Standard Radiographic Projections. Vet. Surgery 38 [2009]: 209-212.
H.A.W. Hazewinkel: Elbow Dysplasia; definitions and clinical diagnoses. Proceedings 23rd Annual Meeting IEWG, Dublin, Ireland [2008]: 5-11.
D.J. Griffon: Elbow Dysplasia in Veterinary Surgery, Vol 1, St. Louis, Elsevier Saunders [2012]: 732-751.
D.L. Piermattei, G.L. Flo, C.E. DeCamp: Handbook of Small Animal Orthopedics and Fracture Repair [ed 4], St. Louis, Elsevier Saunders [2006]: 3-24 & 339-358.
T.W. Fossum: Small Animal Surgery [ed 3], St. Louis, Mosby Elsevier [2007]: 1197-1213.
E. Coppieters, H. Seghers, G. Verhoeven, I. Gielen, Y. Samoy, E. de Bakker, B. van Ryssen: Arthroscopic, CT and Radiographic Findings in 25 Dogs With Lameness After Arthroscopic Treatment of Medial Coronoid Disease. Vet. Surgery 45 [2016]: 246-253.

Mode of inheritance of Elbow Dysplasia and principles of screening methods

H.A.W. Hazewinkel, Em. Prof., DVM, PhD, Dipl. ECVS, Dipl. ECVCN

Introduction

The elbow joint allows for extension and flexion, as well as pronation and supination. In the embryological stage, the elbow joints is a diversity of secondary ossification centers in the distal humerus, proximal radius and proximal ulna; the lateral and medial part of the humeral condyles fuse at the age of 16 weeks, and the anconeal process in some breeds, fuses before the age of 5 months (Voorhout & Hazewinkel, 1987). In some breeds (including Dutch Labradors, Lau et al 2013) the anconeal process develops by apposition, whereas others from an ossifying secondary ossification center (Breit, 2004). The ossification of the coronoid process is complete between 16 weeks (in small breed dogs) and 20 weeks (large breed dogs) (Breit et al, 2004); in Labradors ossification was completed at 20 weeks of age (Seng Fong Lau (2013). Fusion of ossification centers of the elbow vary in different breeds, however also within litters, but not correlated with gender, and environmental factors as dietary intake of the amount of calcium (Voorhout& Hazewinkel, 1987), but not protein (Nap& Hazewinkel, 1993) influence the process of endochondral ossification and thus the age of secondary ossification development and fusion.

Endochondral ossification takes place in an orderly way in growth plates (in physes and cartilage covering epiphyses), but in a more randomly way in the cartilaginous anlage of secondary ossification centers. Disturbance of the process with delay of maturation of the chondrocytes, resulting in immature chondrocytes embedded in unmineralized cartilage matrix, is called ‘osteochondrosis’. With increased loading, or repetitive overloading, or due to heavy weight and heavy exercise, or joint incongruities, this area of unmineralized cartilage is a vulnerable spot inside the joint and may break off its origin. The mechanism of expansion-growth of a socket like the acetabulum and trochlear notch has long been neglected by anatomists: we hypothesize about the cause and consequences of socket disturbance for the elbow joint. The 4 bones of the acetabulum and the 2 bones of the trochlear notch (anconeal and coronoid process) will disperse by the pressure of the growing femoral head or humeral condyle, respectively, and of course not by osteoclastic activity at the surface of these sockets. Elbow incongruity (INC) due to slower growth in length of the radius will cause overloading of the coronoid process of the weight bearing ulna; the medial coronoid apex may break off especially when the coronoid is hereditary vulnerable (as described by Ubbink (1998) in the Bernese Mountain dog). When the ulna is growing more slowly than the radius, the radius may push against the humerus and thus indirectly against the anconeal process: when formed as a secondary ossification center and still cartilaginous attached to the ulna it may detach. However when bony fused, it may cause *distractio cubiti* (as frequently seen in chondrodystrophic breeds at 6 months of age). UAP is described in large breed dogs including the Bernese Mountain Dog, Rottweiler, Mastiff, St. Bernard, Newfoundland, Chow Chow, Labrador Retriever, Golden Retriever, Chinese Shar Pei, English Setter,but also Pomeranian, and Bassett Hound (Grondalen& Lingaas, 1999). When the trochlear notch does not widen properly, increased

pressure can be at the humeral condyle opposite the medial coronoid process and thus causing erosion of the humeral joint cartilage and consequently no joint cartilage and subchondral development at that spot: the so-called “kissing” (=contact) lesion. It may cause osteochondritis dissecans (OCD) of the humeral condyle when joint cartilage is at its later stage of development, causing a detached cartilage flap. When joint cartilage has been fully developed by endochondral ossification, erosions may occur at the superficial layer of the joint cartilage of the distal humeral with secondairy sclerosis of the subchondral bone. This entity of pathological changes in joint cartilage and subchondral bone is referred to as “Medial Coronoid Disease” (MCD, Fitzpatrick et al, 2009). When the trochlear notch does not widen properly (Wind 1986), it may cause pressure points at both sides thus causing an ununited anconeal and a fragmented coronoid process at the same time(Meyer-Lindenberg et al, 2006). When the radio-ulnar joint is not congruent, during pronation and supination a chip of the ulna may break off, especially when not properly developed via endochondral ossification, causing a fragmented coronoid process (Lau et al, 2013).
The fragmented coronoid process (FCP), osteochondritis dissecans (OCD) and ununited anconeal process (UAP) have, according to the hypothesis of Olsson (1977) a shared aetiology with disturbance of endochondral ossification. This may have hereditary and/or non-hereditary origins (Hedhammar et al, 1974; Nap&Hazewinkel 1985, Tryfonidou et al 2003). Other elbow joint abnormalities like Incomplete Humeral Fracture (Marcellin-Little et al, 1994) and radial head subluxation (Temwichitr 2009) could also have a connected ethiology. Little is still known about etiologies other than disturbance of endochondral ossification in all the entities of Elbow Dysplasia (ED), however biomechanical changes may be (in addition) responsible for the occurrence of one or more entities of ED.
From the above, it will be clear that different disturbances in skeletal development may have the same consequences and more etiologies may be responsible for ED. In the Labrador and Golden retriever mainly FCP and OCD are seen (Padgett et al, 1995; Studdert et al, 1998; Lavrijsen 2014), whereas in Bernese Mountain dogs (BMD) FCP is mostly seen together with elbow incongruity (INC) with a too short radius (Ubbink, 1998; Lavrijsen 2014) equally distributed over the sexes. Ubbink (1998) calculated that FCP and INC in BMD were originating from different groups of ancestors in the BMD population, and that 80% of the BMDs suffering from ED had both FCP and INC.

Genetics

Studying the genetic basis of FCP, in combination with family data, could improve our understanding of the etiology in the breed. Since collagen genes are involved in extracellular matrix of cartilage and bone, especially during the period of skeletal development, these genes were considered to be promising candidate genes, despite the disadvantage for genetic research that FCP is not described in other (laboratory) species. Mutated causative genes are expected to be frequently shared by affected sib-pairs. Several collagen genes (COL1A1, COL1A2, COL2A1, COL3A1, COL5A1, COL5A2, COL6A3, COL9A1, COL9A2, COL9A3, COL10A1, COL11A1, COL11A2, and COL24A1 were found not to be responsible for FCP in a cohort of Labrador retrievers with or without FCP. With fine-mapping, loci linkaged to FCP were indicated on chromosome 1 and 13, although the genes have still to be identified (Temwichitr 2009). The research for the responsible

gene(s) has to deal with several complicated factors (1) based on the wide spread of the disease it is most likely a complex disease which is as a consequence hard to elucidate (Risch & Merikangas, 1996), (2) it is hard to collect DNA samples from whole families both certainly with FCP and control families certainly without FCP, and (3) it is hard to diagnose with 100% certainty dogs free or affected by FCP by radiographs. From earlier studies it was made likely that the mode of inheritance of FCP in Labradors is a 'major gene with some minor polygenic effects' model (although the major cause could be dominant of recessive)(Everts, 2000). Predisposition of male Labradors, could be that the disease inherit in a dominant fashion with a reduced penetrance in female dogs, or could cause predisposing factors as weight gain and growth rate velocity and heavy exercise (Everts 2000). By Mäki (2004) FCP is considered to be polygenetic and multifactorial. From recent studies in developing Labrador puppies, born from two FCP-affected parent dogs, it became clear that till 18 weeks of age FCP is only a fracture of the subchondral bone with delayed endochondral ossification, and later a fracture in the overlying articular cartilage will take place (Seng Fong Lau 2013). Based on the clinical experience that FCP can become manifest even at advanced age (van Bruggen et al 2010), it may be concluded that cartilage damage will be conditional for elbow lameness, and will be secondary from the subchondral lesion. Not cartilage damage itself (cartilage is aneural), but the secondary inflammatory reactions as sclerosis of the subchondral bone and other secondary artrotic manifestations (osteophytosis, synovitis, joint effusion and pain) play a role in clinical FCP. Since radiology has a poor sensitivity to register FCP itself (0% in young dogs, 10-62% in clinical cases, Lau et al, 2013), the diagnosis in clinical practice and in screening programs, is also focussed on these secondary signs. Less than 3 views for screening will underestimate the presence of ED in around 20% of the cases, especially with OA grade <2. (Lang et al, 1998, Hazewinkel et al 1998)

Screening

One of the basic rules of radiology is the need of orthogonal views to detect abnormalities counts also thru for elbow dysplasia (Lang et al 1998, Hazewinkel et al, 1998, Mäki et al, 2004, Lappalainen, 2014). The radiographic abnormality most strongly correlated with FCP was sclerosis of the trochlear notch in a survey of 7300 cases (Lavrijsen et al, 2012) as visible on the mediolateral view. Also the contours on the medial humeral condyle and of the medial coronoid process ("f" and "g", respectively, on the IEWG screening form) are also highly correlated with FCP (95% in Labradors, 92% in Goldens and 95% in Bernese Mountain dogs), and visible on the anterior-posterior (AP) view. In addition the AP view in necessary to diagnose OC and OCD(-like) lesions as present in Labradors (13.2%) and Golden Retrievers (25.4% of that study (Lavrijsen 2014) Taking at least two radiographic projections for ED screening would decrease the number of false negative cases and increase the accuracy of the breeding value estimation (Lang et al, 1998). Selection conducted thus far against elbow dysplasia has been very weak. The estimated genetic trends showed only a small genetic gain in all breeds for elbow dysplasia sofar (Mäki, 2004, Lavrijsen 2014). Age at radiographic examination has been indicated as significantly associated with OA in case of ED (Swenson et al, 1997; Maki et al 2000; Malm et al 2008). From a longitudinal study in Labradors without pathology of their medial coronoid process, increasing OA

with increasing age was demonstrated (Huck et al 2009). Potentially screening at older age may increase the chance of false positive diagnosis of ED, especially when the screening is determined by the degree of OA on a ML-flexed view. This underscores the necessity of screening at the same age group (Mäki 2004).
Using data of relatives allow for a more accurate estimation of the genetic ability of the potential breeding stock, this is especially thru for traits with a low heritability (~0.15). When at least some of the pups from each litter are ad randomly screened, this wouls add to the knowledge of the parent animals and could add to a more accurate estimation of the genetic ability, expressed as estimated breeding value (EBV). In dendrograms, Ubbink (1998) demonstrated that at that time family groups of Labradors (with maximum 1/8th of the genome in common) contained between 50% and 0% FCP-affected animals demonstrating that certain families are at risk, whereas others are not at all. Heritabilities can be underestimated when breeding candidates are pre-selected (e.g. not screened due to clinical signs and treatment at young age, or dogs not participating in the official screening program on request of the owner). The severe and obvious cases will be excluded and thus the phenotypic and therefore the genetic variation will be underestimated.
DNA screening would be the solution of tracing the potential positive breeding stock, for these orthopedic diseases as well as for other undesarible traits and prevent inbreeding at the same time. Since orthopedic diseases like FCP, OCD, UAP, INC have a polygenic inheritance, a simple gene test cannot be developed for these diseases. Even without knowledge of the causative mutation, but when markers associated with the diseases status are identified, these markers can be used in a screening panel. These markers should be close to the causative mutation on the chromosome, to have a linkage disequilibrium (LD) of 100%, i.e. the marker shows the same inheritance pattern as the mutation. More markers in a test increase the chances to be linked to the involved causative mutations along the chromosomes involved. To develop these tests, many DNA samples of populations of 100%-certain positive and 100%-certain negative dogs for the trait, and the corresponding funding are necessary. A proper screening of these populations has to preceed the marker development. It is the resposibility of the breeder clubs to organise the development of these DNA-tests.
Currently, selection of the potential breeding dog is based on its phenotype (negative for ED) with unavitable screening bias. When taking information of litter mates of a potential breeding dog into consideration, the screening bias can be reduced. Taking the EBV into account, based on the phenotype of additional related animals, will further improve the selection (Malm et al, 2011). In genomic EBV (gEBV) DNA information based on genome wide assiociation studies will further improve the selection of these and other traits in these dog breeds (Daetwyler, 2013, Lavrijsen 2014).
Optimal phenotypic screening should be performed by skilled radiologists or veterinary surgeons in a standardized fashion, on at least two orthogonal radiographs (ML and AP) of both elbow joints of good quality made from a mature dog (>12 months of age). A certificate should be handed over tot he owner/breeder which is transparent for the quality of screners, and the amount of radiographst he screening was based on (Figure 1). Positive dogs should not be used for breeding, and consequences has to be drawn for related dogs. Two positive dogs can have ED-negative offspring, and phenotypic negative dogs can have positive offspring. It is therefore of great importance to check as many

offspring as possible. Only thorough measures will improve the genetic trend enough (Mäki, 2004; Lavrijsen 2014)

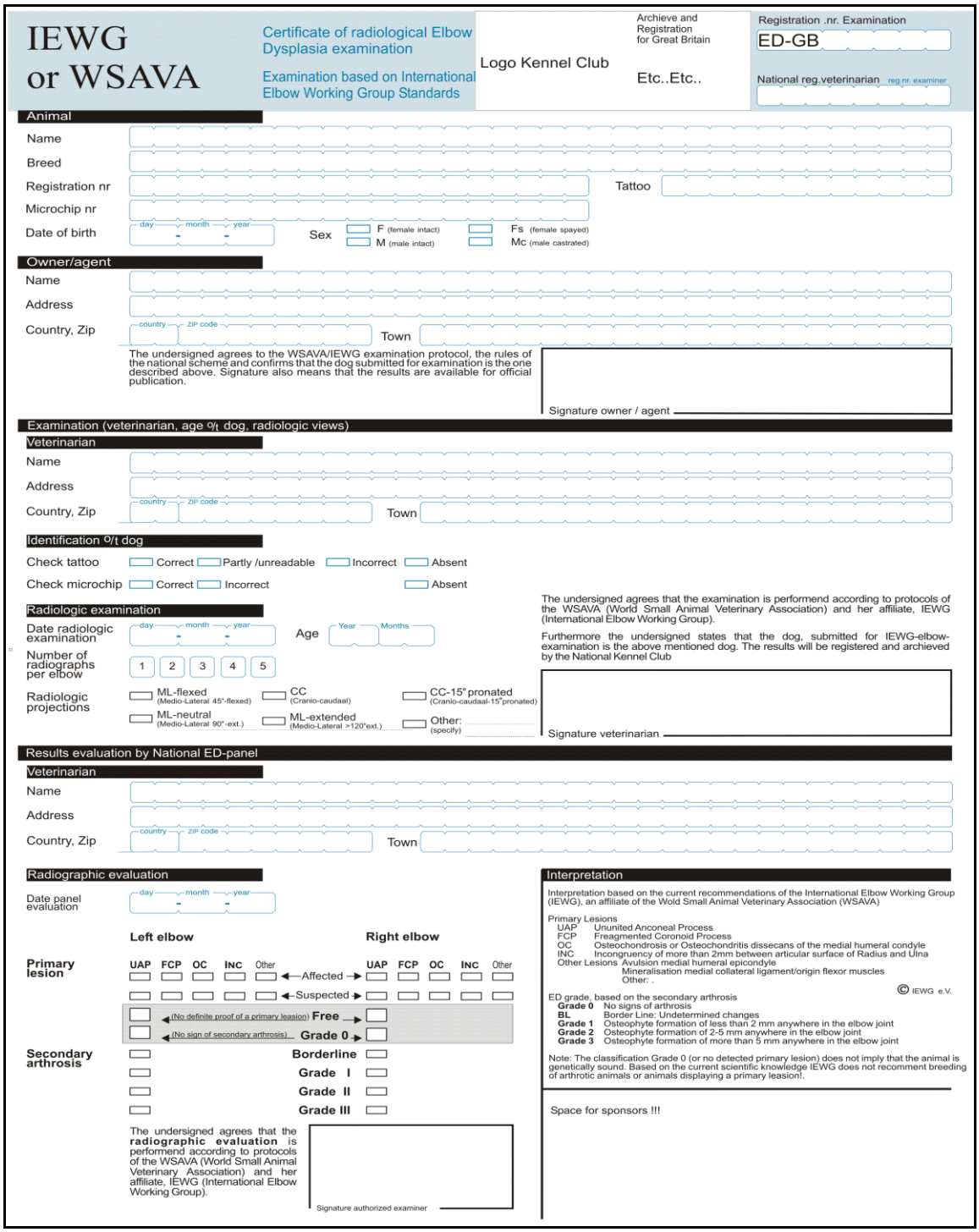

IEWG or WSAVA

Certificate of radiological Elbow Dysplasia examination

Examination based on International Elbow Working Group Standards

Logo Kennel Club

Archieve and Registration for Great Britain

Etc..Etc..

Registration .nr. Examination

ED-GB

National reg.veterinarian reg.nr. examiner

Animal

Name

Breed

Registration nr

Tattoo

Microchip nr

Date of birth day month year

Sex F (female intact) Fs (female spayed) M (male intact) Mc (male castrated)

Owner/agent

Name

Address

Country, Zip country ZIP code

Town

The undersigned agrees to the WSAVA/IEWG examination protocol, the rules of the national scheme and confirms that the dog submitted for examination is the one described above. Signature also means that the results are available for official publication.

Signature owner / agent

Examination (veterinarian, age o/t dog, radiologic views)

Veterinarian

Name

Address

Country, Zip country ZIP code

Town

Identification o/t dog

Check tattoo Correct Partly /unreadable Incorrect Absent

Check microchip Correct Incorrect Absent

Radiologic examination

Date radiologic examination day month year

Age Year Months

Number of radiographs per elbow 1 2 3 4 5

Radiologic projections ML-flexed (Medio-Lateral 45°-flexed) CC (Cranio-caudaal) CC-15° pronated (Cranio-caudaal-15° pronated) ML-neutral (Medio-Lateral 90°-ext.) ML-extended (Medio-Lateral >120°ext.) Other: (specify)

The undersigned agrees that the examination is performend according to protocols of the WSAVA (World Small Animal Veterinary Association) and her affiliate, IEWG (International Elbow Working Group).

Furthermore the undersigned states that the dog, submitted for IEWG-elbow-examination is the above mentioned dog. The results will be registered and archieved by the National Kennel Club

Signature veterinarian

Results evaluation by National ED-panel

Veterinarian

Name

Address

Country, Zip country ZIP code

Town

Radiographic evaluation

Date panel evaluation day month year

	Left elbow						Right elbow				
Primary lesion	UAP	FCP	OC	INC	Other		UAP	FCP	OC	INC	Other
						◄ Affected ►					
						◄ Suspected ►					
						◄ (No definite proof of a primary leasion) Free ►					
						◄ (No sign of secondary arthrosis) Grade 0 ►					
Secondary arthrosis						Borderline					
						Grade I					
						Grade II					
						Grade III					

The undersigned agrees that the **radiographic evaluation** is performend according to protocols of the WSAVA (World Small Animal Veterinary Association) and her affiliate, IEWG (International Elbow Working Group).

Signature authorized examiner

Interpretation

Interpretation based on the current recommendations of the International Elbow Working Group (IEWG), an affiliate of the Wold Small Animal Veterinary Association (WSAVA)

Primary Lesions
UAP Ununited Anconeal Process
FCP Freagmented Coronoid Process
OC Osteochondrosis or Osteochondritis dissecans of the medial humeral condyle
INC Incongruency of more than 2mm between articular surface of Radius and Ulna
Other Lesions Avulsion medial humeral epicondyle
Mineralisation medial collateral ligament/origin flexor muscles
Other: .

© IEWG e.V.

ED grade, based on the secondary arthrosis
Grade 0 No signs of arthrosis
BL Border Line: Undetermined changes
Grade 1 Osteophyte formation of less than 2 mm anywhere in the elbow joint
Grade 2 Osteophyte formation of 2-5 mm anywhere in the elbow joint
Grade 3 Osteophyte formation of more than 5 mm anywhere in the elbow joint

Note: The classification Grade 0 (or no detected primary lesion) does not imply that the animal is genetically sound. Based on the current scientific knowledge IEWG does not recomment breeding of arthrotic animals or animals displaying a primary leasion!.

Space for sponsors !!!

Figure 1.
Certificate of the IEWG for screening of elbow joint. The certificate gives insight in the responsible veterinarians
involved in making and judging the radiographs, the identification of the dog, the amount of radiographical views
the grading was based on, and the final grading of the OA and presence of primary lesions UAP, FCP, OC, and/or INC.

References

Breit S, Künzel W, Seiler S (2004) variation in the ossification process of the anconeal and medial coronoid process of the canine ulna. Research in Veterinary Science 77, 9-16

Daetwyler HD, Calus MP, Pong-Wong R, de Los Campos G, Hickey JM (2013). Genomic prediction in animals and plants: simulation of data, validation, reporting, and benchmarking. Genetics 193:347-365

Everts R (2000) Molecular genetic studies in the dog: application to fragmented coronoid process (FCP) in the Labrador retriever. Thesis Utrecht University.

Fitzpatrick N, Yeadon R (2009) Working algorithm for treatment decision making for the developmental diseases of the medial compartment of the elboe in dogs. Vet Surg 38, 285-300

Grondalen J*,* Lingaas F*:* Screening for elbow arthrosis (elbow dysplasia) in Norway*.* Eur J Comp Anim Pract 1999*;9:*113–115

Lavrijsen IC[1], Heuven HC, Voorhout G, Meij BP, Theyse LF, Leegwater PA, Hazewinkel HA (2012) Phenotypic and genetic evaluation of elbow dysplasia in Dutch Labrador Retrievers, Golden Retrievers, and Bernese Mountain dogs. Vet J. 193:486-492.

Lang J, Busato A, Baumgartner D, Flückiger M, Weber UT (1998) Comparison of two classification protocols in the evaluation of elbow dysplasia in the dog. JSAP 39, 169-174

Hazewinkel HAW, Meij BP, Theyse LFH Surgical treatment of elbow dysplasia Vet Quart 20 Suppl 1, 29-31

Hedhammar A, Wu FM, Krook L. (1974) Overnutrition and skeletal disease. An experimental study in growing Great Dane dogs. XI. Summary. Cornell Vet.64:Suppl 5:128-135.

Huck JL, Biery DN, Lawler DF, Gregor TP, Runge JJ, Evans RH, Kealy RD, Smith GK.(2009) A longitudinal study of the influence of lifetime food restriction on development of osteoarthritis in the canine elbow.Vet Surg.38:192-198

Lappalainen A. (2013) Radiographic Screening for Hereditary Skeletal Disorders in Dogs, thesis University of Helsinki

Lau SF, Hazewinkel HA, Grinwis GC, Wolschrijn CF, Siebelt M, Vernooij JC, Voorhout G, Tryfonidou MA.(2013) Delayed endochondral ossification in early medial coronoid disease (MCD): a morphological and immunohistochemical evaluation in growing Labrador retrievers.Vet J. 197:731-738

Lavrijsen I (2014) Genetics of Hip dysplasia, elbow dysplasia and patellar luxation, Thesis Utrecht University

Mäki K. (2004) Breeding Against Hip and Elbow Dysplasia in Dogs, Thesis University of Helsinki,

Malm S[1], Fikse WF, Danell B, Strandberg E. (2008) Genetic variation and genetic trends in hip and elbow dysplasia in Swedish Rottweiler and Bernese Mountain Dog. J Anim Breed Genet. 125:403-412

Marcellin-Little DJ, DeYoung DJ, Ferris KK, Berry CM.(1994) Incomplete ossification of the humeral condyle in spaniels. Vet Surg. 23:475-487

Meyer-Lindenberg a, Fehr M, Nolte I (2006) C0-existence of ununited anconeal process and fragmented coronoid process of the ulna in the dog JSAP 47, 61-65

Nap RC, Hazewinkel HA. (1994) Growth and skeletal development in the dog in relation to nutrition; a review. Vet Q. 16:50-59.

Olsson S.-E. (1977) Osteochondrosis in the dog, in : Kirk RW (ed) Current Veterinary Therapy VI, small animal practice WB Saunders Comp, Philladelphia pp. 880-886.

Padgett GA, Mostosky UV Probst CW, Thomas MW Krecke CF. (1995) The inheritance of ocd and fcp of the elbow joint in Labrador retrievers JAAHA 31, 327-330.

Risch N, Merikangas K. (1996) The future of genetic studies of complex human diseases. Science.13; 273

Seng Fong Lau (2013) Development of medial coronoid disease in Labrador retrievers: diagnostic and pathogenic studies. Thesis Utrecht University

Studdert VP, Lavelle RB, Beiharz RG, Mason TA, (1991) Clinical features and heritability of ocd of the elbow in Labrador retrievers JSAP 32, 557-563.

Temwichitr j.(2009) The genetic defect of fragmented coronoid process in Labrador retrievers and other skeletal diseases in dogs. Thesis Utrecht University

Tryfonidou MA, Holl MS, Stevenhagen JJ, Buurman CJ, Deluca HF, Oosterlaken-Dijksterhuis MA, van den Brom WE, van Leeuwen JP, Hazewinkel HA. (2003) Dietary 135-fold cholecalciferol supplementation severely disturbs the endochondral ossification in growing dogs. Domest Anim Endocrinol.24:265-285

Ubbink G. (1998) Hererited disease in purebred dog populations: predictions based on common ancestry. Thesis Utecht University

Voorhout G, Hazewinkel HAW. (1987) Radiographic evaluation of thecanine elbow joint with special reference tot he medial humeral condyle and medial coronoid process Veterinary Radiology 28, 158-165.

Van Bruggen LW, Hazewinkel HAW, Wolschrijn CF, Voorhout G, Pollak Y, Barthez PY (2010) Bone scintigraphy fort he diagnosis of an abnormal medial coronoid process in dogs. Vet Radiol&Ultrasound 51, 344-348

Wind A.(1986) Elbow incongruity and developmental elbow diseases in the dog, part I. JAVMA 22, 711-724.

Explanation of the IEWG grading system

S. Ohlerth, PD Dr. med. vet. Dipl. ECVDI, B. Tellhelm, Dr. med. vet., Dipl. ECVDI, K. Amort , Dr. med. vet. Dipl ECVDI, N. Ondreka, Dr. med. vet., Dipl. ECVDI

The diagnosis of canine elbow dysplasia (ED) in screening programs is based on the evaluation of radiographs according to the protocol of the International Elbow Working Group (IEWG). The most recent update of this protocol is available on the IEWG web site (http://www.iewg-vet.org). A mediolateral flexed projection of each elbow joint is mandatory for interpretation and an additional craniocaudal pronated view is highly recommended. The IEWG protocol registers signs of arthrosis and the presence of major primary lesions (FCP, OCD, UAP, Incongruity). Films are evaluated in a two-stage process: a) assessing the degree of secondary degenerative joint disease (arthrosis) and b) checking for signs of a primary lesion.

Any other abnormal finding should also be reported.

The status of the elbow joint regarding arthrosis is scored as either “normal” (Grade 0), mild (Grade 1, osteophytes less than 2 mm high anywhere in the joint), moderate (Grade 2, osteophytes 2 – 5 mm high) and severe (Grade 3, osteophytes higher than 5 mm). In the updated protocol the severity of joint incongruity has been included.

The primary lesions have been defined by the IEWG (for details see the IEWG website).

Scoring (updated 2010)
The elbow findings are scored according to the severity of arthrosis (DJD) and/or the presence of a primary lesion.

Elbow Dysplasia Scoring		Radiographic Findings
0	Normal elbow joint	Normal elbow joint, No evidence of incongruency, sclerosis or arthrosis
1	Mild arthrosis	Presence of osteophytes < 2 mm high, sclerosis of the base of the coronoid process - trabecular pattern still visible
2	Moderate arthrosis or suspected primary lesion	Presence of osteophytes of 2 - 5 mm high Obvious sclerosis (no trabecular pattern) of the base of the coronoid processes Step of 3-5 mm between radius and ulna (INC) Indirect signs for a primary lesion (UAP, FCP/ MCD, OCD)
3	Severe arthrosis or evident primary lesion	Presence of osteophytes of > 5 mm high Step of > 5 mm between radius and ulna (obvious INC) Obvious presence of a primary lesion (UAP, FCP, OCD)

A Borderline (BL) score between ED 0 and ED 1 is allotted to dogs with minimal anconeal process modelling of undetermined etiology in some countries (i. g. Germany, France, Italy).

How many projections?
The minimal requirement is a true ML projection of each elbow. Excessive pronation or supination should be avoided. In a maximally flexed position (as it is the standard view in many countries) the elbow is often markedly supinated, making correct interpretation of shape and structure of MCP, sclerosis caudal to MCP and spur formation cranially difficult.

An OC defect may easily be missed on the ML projection, but can usually be identified on a CrCd 15° pronated view. As scrutineers in many European countries (e.g. Scandinavia, UK) ask only for a maximally flexed ML view or two ML views with different flexion of the elbows respectively, an OC lesion may not be recognized.

For many years a Cr15L-CdMO pronated view was considered mandatory for the diagnosis of FCP. However recent results of CT examinations and arthroscopy indicate that radiological findings typical for the presence of FCP can be identified on the ML view quite consistently. The ML projection may therefore be sufficient to diagnose or suspect the presence of a FCP reliably in a screening program. As reported before, two ML-projections - flexed (30°-40°) and neutral (100° - 120°) position - give the best information concerning shape and structure of MCP and are also diagnostic for incongruity and osteophytes. On radiographs of good quality even many OC lesions are visible on the flexed ML.

How to score ED?
ED scoring on the basis of a combination of the severity of arthrosis (DJD) and radiographic findings indicative for a primary lesion or evidence of a primary lesion is not uniformly used in Europe and overseas. The Scandinavian countries for example started scoring in the early 80ies prior to the foundation of IEWG. Their classification is based on the degree of arthrosis, while of the primary lesions only UAP is recorded. This scoring system is used in Scandinavia and also in the UK and USA/Canada.

The most common primary elbow lesion is a FCP. Pertinent radiological findings on the ML projection are a blurred and deformed cranial edge of the medial coronoid process (MCP), a reduced opacity of its tip, an increased opacity of the ulnar notch at the level of the coronoid processes and an increased and/or incongruent joint space between humerus and radius. It is important to recognize that even minimal changes are usually pathognomonic for FCP qualifying an elbow for at least an ED grade 2 (moderate ED, suspected medial coronoid disease/ FCP) according to the current IEWG protocol regardless of the height of osteophytic new bone formation. The severity of new bone formation is quite variable and some dogs may not show any new bone formation at all. If grading is based on the size of the osteophytes only, many elbows with FCP will be underscored and may even be considered free of ED.

Beware of conflicting data
As mentioned above the IEWG scoring system is a two-step procedure, a) assessing the degree of arthrosis and b) registering any signs indicative of a primary form of ED. Bear in mind that various countries in Europe and overseas only rely on step a). Both concepts have proven to be useful in reducing ED in a population. However problems arise when dogs are to be used for breeding in countries with differing scoring system. In such a case it is advised to re-score the dog again according to the local scoring mode. It will be the aim of IEWG to harmonize the scoring systems in the future.

Computed tomography (CT) imaging and appeal procedure
Diagnosing FCP radiographically may be based on subtle findings which may be difficult to convey to the dog owner. As a consequence an increasing number of appeals are filed and owners ask for a CT study to be included in the re-evaluation process. No standardized protocol for CT examination of the canine elbow have been proposed. IEWG plans to install a standardised protocol for appeal procedures, the use of CT and/or MRI examinations and the technical requirements of such studies.

Elbow Dysplasia: Computed tomography standards, protocols and quality assurance

Dr. K.H. von Pückler DipECVDI, Dr. N. Ondreka DipECVDI, Dr. B. Tellhelm Dip ECVDI.

During the last decades computed tomography (CT) has increasingly gained importance in diagnosing diseases of the appendicular skeleton. Several investigations showed that CT is an important tool for the accurate and non-invasive assessment of elbow dysplasia including medial coronoid disease. After comparison of radiography, CT and arthroscopy in clincal cases Villamonte-Chevalier and co-workers (2015) state that due to its high sensitivity and specificity CT should be the prefered technique for the assessment of lesions of the canine elbow joint. Other studies come to comparable results. While the accuracy of radiography in clincal cases of ED is described to be high CT is superior in questionnable cases and is commonly used for equivocal breeding cases.

Although CT has widely been used for the mentioned cases of medial coronoid pathology no clear and complete description of standard protocols is available so far. Previous reviews and studies gave variable recommendations regarding indication, planning and set up. Only few prospective studies regarding the technical details have been performed. The result is an extensive heterogeneity of the effectively applied scanning protocols in everyday clinical practice and breeding cases.

One of the most important parameters is the scanning slice thickness. Different CT scanners provide a range of selectable slice thicknesses from less than 0.5 mm up to 5 mm in width. The minimum possible slice thickness is dependent on the detector conformation of the scanner. Cook and Cook (2009) previously suggested to use a slice thickness less than 2 mm in width based on their experience. Althought this information is available several institutions still use slice thicknesses of 2 mm or more for the assessment of coronoid pathology in dogs. This is the background for a recent study comparing the use of 1, 2 , and 3mm slices in clinical cases. The results of the study support the impression of Cook and Cook (2009) showing that 2 an 3 mm slices are inferior and sometimes even non-diagnostic compared to 1 mm slices.

Patient position has also been discussed extensively and there is a wide variation of positionings performed at different institutions in everyday clinical practice. Special regard should be on the avoidance of artifacts due to beam hardening or disadvantageous relation of the anatomical axis to the centre of the scanner. A recent study (Fehrlage et al. under review) shows that rotation of the elbow joint along its longitudinal axis as well as sternal, dorsal or lateral positioning of the patient have no impact on the assessment of the medial coronoid process. A particularly important factor is the avoidance of beam hardening artifacts by the head of the patient. This means that the head of the patient is flexed laterally or caudally to avoid superimposition with the elbows- regardless the positioning of the patient.

Tube current and reconstruction algorithms should fit the needs of the pictured structures. A high detail (bone) kernel should be combined with sufficient high tube current and voltage to avoid noise and hardening artifacts or photon starvation. Extreme edge anhencement should be avoided.

Quality assurance and regular maintainance of the equipment is an obligation in human medicine. Although these preocedures are not obligatory for veterinary medicine in most countries an inspection of the equipment as well as conditioning of the detectors and registration of measurement faults should be part of daily routine. The inspection of the hardware should be performed on a regular base according to the recommendation of the manufacturer.

Viewing and reporting of CT images requires a quiet invironment and ambient light. The optimal depiction regarding window width and level for the assessment of medial coronoid disease has been described by Tromblee and co-workers in 2007: different display window width and window level settings have been compared. Changes of the subchondral bone were most reliably assessed with a window width of 3500 HU while the visualization of changes in conformation of the elbow joint including the medial coronoid process and incongruity was mostly influenced by the image plane.

In conclusion there are multiple influences that may impair the correct assessment of elbow dysplasia via CT. Further work is needed to establish protocols for international standard procedures. At the moment a slice thickness of maximum 1mm and a positioning without superimposition of the head are required.

Canine elbow dysplasia

-CT based assessment & grading-

N. Ondreka,
K. von Pückler, B. Tellhelm

Small Animal Clinic - Radiology
Justus Liebig University Gießen, Germany

in cases with suspected medial coronoid disease

Rau et al. Observer variability and sensitivity of radiographic diagnosis of canine medial coronoid disease. Tierärztliche Praxis Kleintiere 2011

- **X-rays versus arthroscopy**

Observer	Student	Doctoral student	Resident	Diplomate	CT
Sensitivity %	77.2	80.4	92.4	96.7	100

Primary lesions	Osteoarthritis
MCD	Borderline
OCD	< 2 mm
INCONGRUITY	2 – 5 mm
UAP	> 5 mm

MCD

Fragment

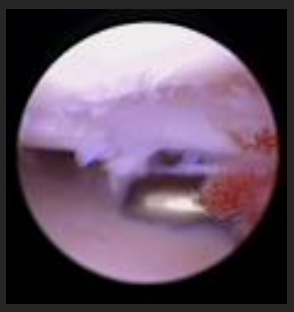

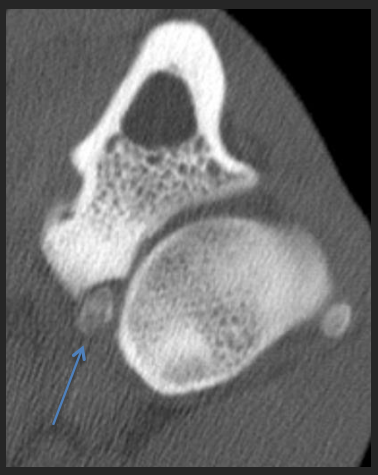

Moores et al. Computed Tomography Versus Arthroscopy for Detection of Canine Elbow Dysplasia Lesions. Vet Surg 2008

MCD

Fissure

→ Non-displaced fragment

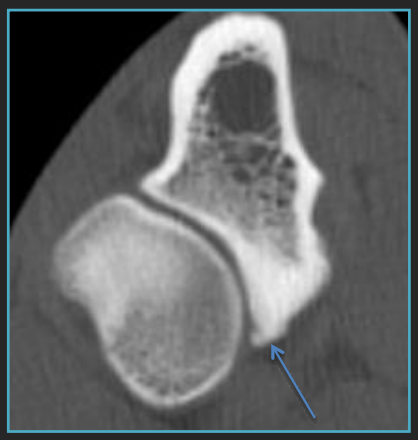

Moores et al. Computed Tomography Versus Arthroscopy for Detection of Canine Elbow Dysplasia Lesions. Vet Surg 2008

MCD

Osteophytes

→ Cartilage erosion medial compartment

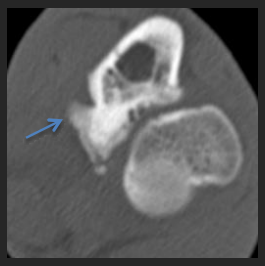
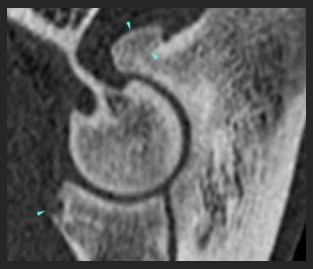
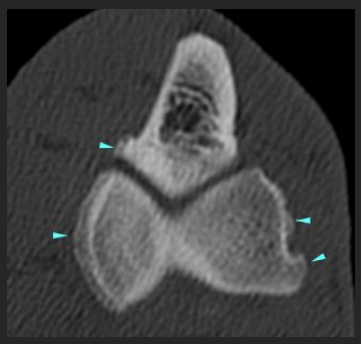

Moores et al. Computed Tomography Versus Arthroscopy for Detection of Canine Elbow Dysplasia Lesions. Vet Surg 2008

Elbow dysplasia

OCD

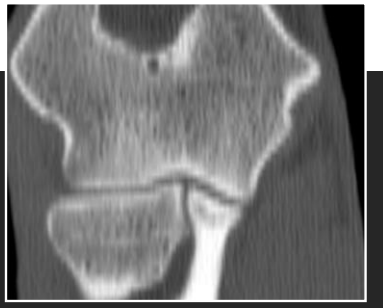
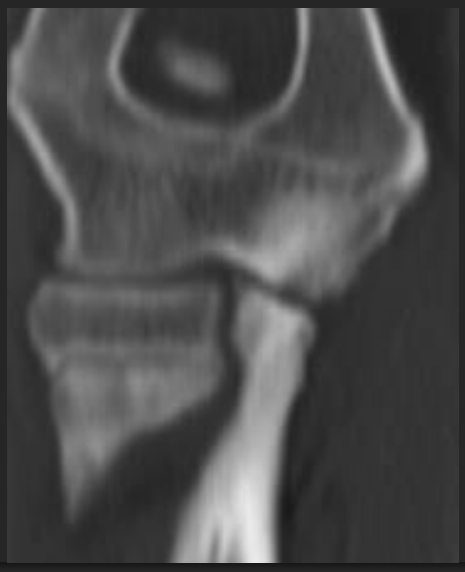


Elbow dysplasia

RU INCONGRUITY

CT of great value in vitro

Midcoronoid oblique reconstructions most accurate

CT less accurate than arthroscopy but more accurate than rads
Radiography reasonable sensitivity steps > 2 mm

Blond et al. Sensitivity & specificity of radiographic detection of canine elbow incongruence in an in vitro model. *VRU* 2005

Holsworth et al. Accuracy of computerized tomographic evaluation of canine radioulnar incongruence in vitro. *Vet Surg* 2005

Wagner et al. Radiographic, computed tomographic, and arthroscopic evaluation of experimental radioulnar incongruence in the dog. *Vet Surg* 2007

Samoy et al. Computed Tomography Findings in 32 Joints Affected with Severe Elbow Incongruity and Fragmented Medial Coronoid
Process. Vet Surg 2012

RU INCONGRUITY

Cyst at the radioulnar transition

Fragmentation of the axial border of the medial coronoid

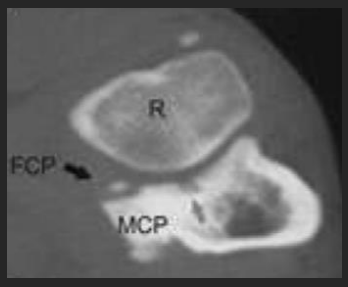

Samoy et al. Computed Tomography Findings in 32 Joints Affected with Severe Elbow Incongruity and Fragmented Medial Coronoid
Process. Vet Surg 2012

Irregularity of the radial incisure
Sclerosis/lucency of the MCP
Sclerosis of the humeral condyle
Ulnar subtrochlear sclerosis

Expression of early pathology or normal variant??

Irregular incisure

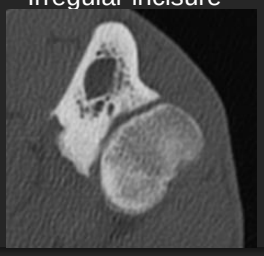

Sclerotic MCP

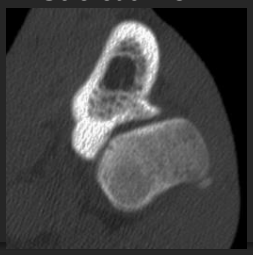

Sclerotic trochlea

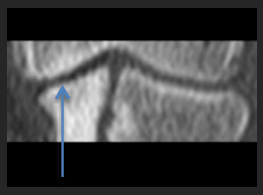

Subtrochlear sclerosis

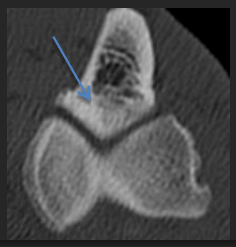

Elbow dysplasia

Irregular radial incisure

→ Cartilage erosion MCP

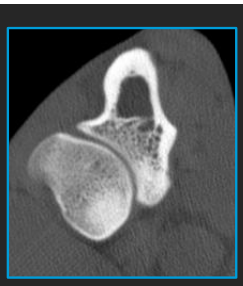

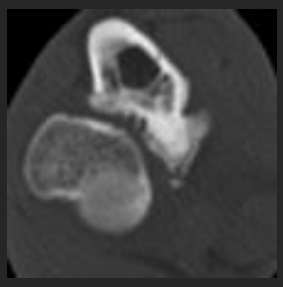

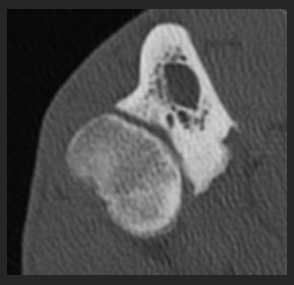

Moores et al. Computed Tomography Versus Arthroscopy for Detection of Canine Elbow Dysplasia Lesions. Vet Surg 2008

Elbow dysplasia

Sclerosis/lucency of the MCP
Sclerosis of the humeral condyle
Ulnar subtrochlear sclerosis

(n = 101)
→ Not significantly associated with MCD

Clarification warranted: comparison between dogs with medial compartment disease with breeds not prone to elbow dysplasia

Moores et al. Computed Tomography Versus Arthroscopy for Detection of Canine Elbow Dysplasia Lesions. Vet Surg 2008

Elbow dysplasia

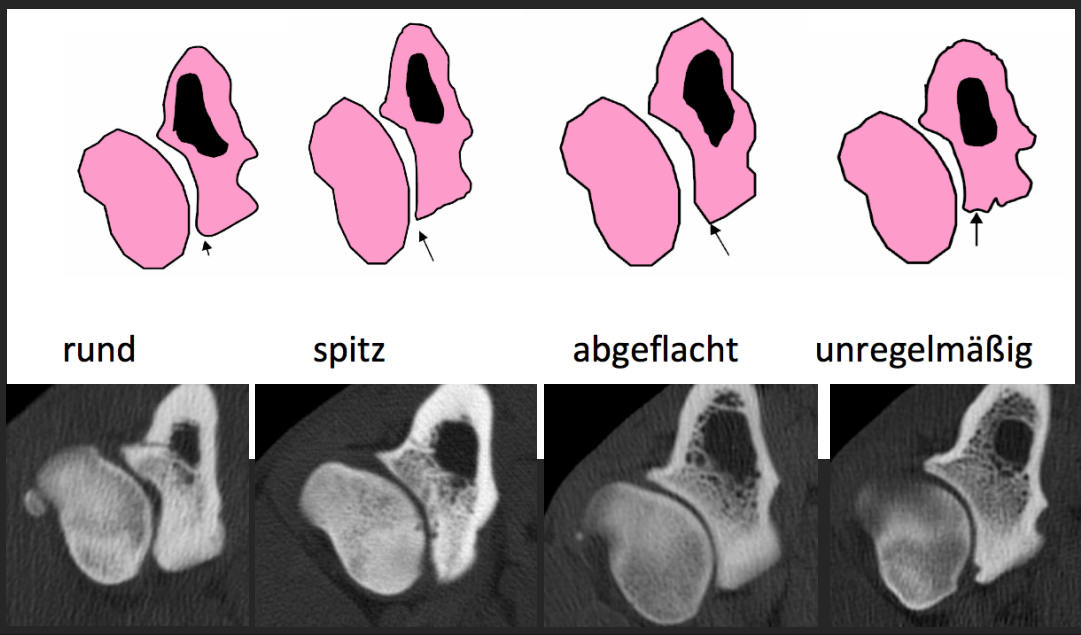

Elbow dysplasia

X-ray cases with ill defined MCP = ED 2?

Influence of breed, joint conformation, others…

CT in cases of appeal

„New“ radiographs from an university:

Elbows ML neutral, ML flexed, CrCd 15° pron

Optional: CT

RADIOGRAPHIC AND COMPUTED TOMOGRAPHY FINDINGS IN BELGIAN SHEPHERD DOGS WITH MILD ELBOW DYSPLASIA

Anu K. Lappalainen, Sari Mölsä, Annie Liman, Outi Laitinen-Vapaavuori, Marjatta Snellman

We compared computed tomography (CT) and radiographic findings of Belgian shepherds with grade 1 or borderline elbow dysplasia to determine whether the radiopaque area dorsal to the anconeal process and seen in mediolateral 45° flexed radiographs is formed by osteophytes, or whether it is an anatomic variation. Eighteen dogs with screening results 0/1, 1/0, or one or both elbows graded as borderline were studied. The radiographs were evaluated according to International Elbow Working Group guidelines and compared with CT images. A fragmented medial coronoid process was seen in five joints, and remaining 31 joints were considered free of dysplasia based on CT images. In radiographs, height of the radiopaque area on the anconeal process was 0–2.7 mm in dysplastic and 0–3.0 mm in other joints. Sensitivity of this sign as dysplasia indicator was 40% and specificity 29%. All dysplastic joints and three of the other joints had blurring of the cranial edge of the medial coronoid process. Subtrochlear sclerosis was seen in four dysplastic joints and in three other joints. Both changes were significant indicators of dysplasia ($P<0.001$). Sensitivity and specificity of these phenomena as dysplasia indicators were 80% and 90%, respectively. We conclude that the radiopaque area on the anconeal process might not always be osteophyte formation in Belgian shepherds and should not be used as the sole criterion for dysplasia. Blurring of the medial coronoid process cranial edge and ulnar trochlear notch sclerosis are reliable signs of elbow dysplasia and may be beneficial in screening protocols. *Veterinary Radiology & Ultrasound, Vol. 50, No. 4, 2009, pp 364–369.*

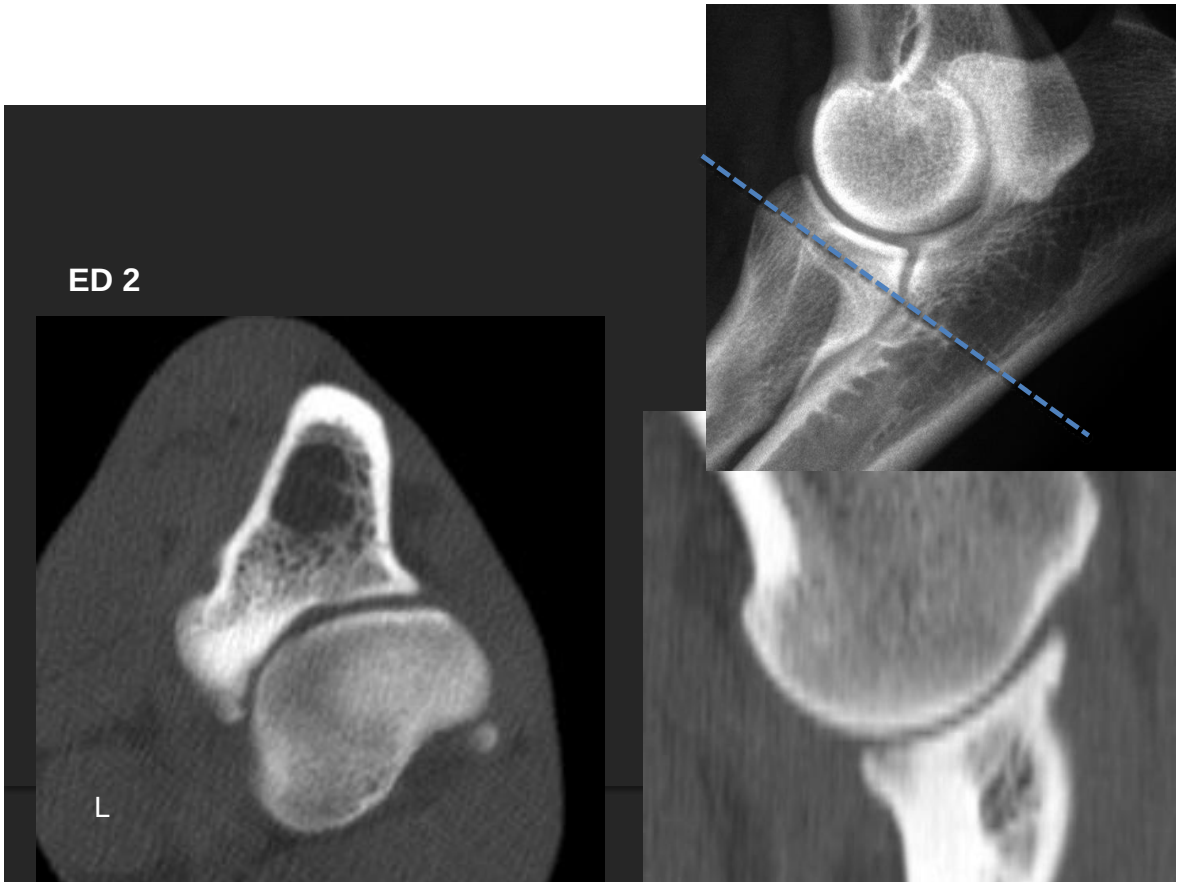
ED 2
L

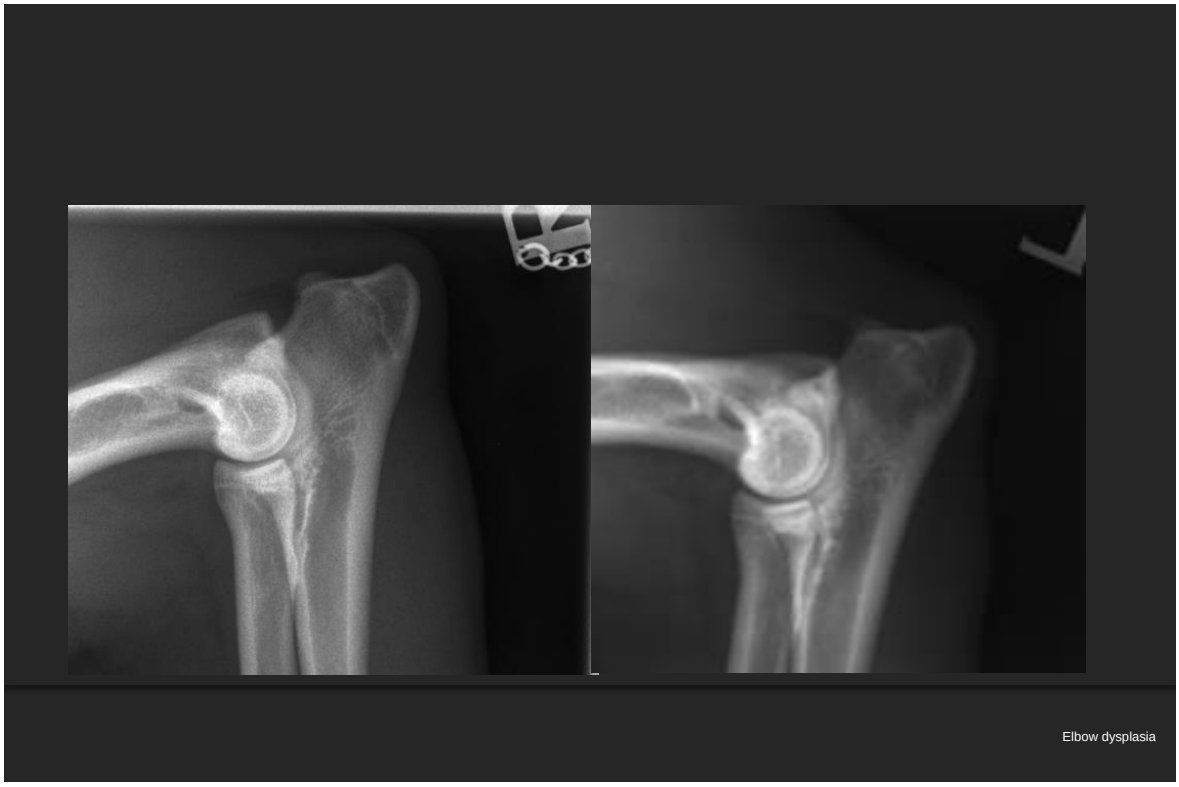
Elbow dysplasia

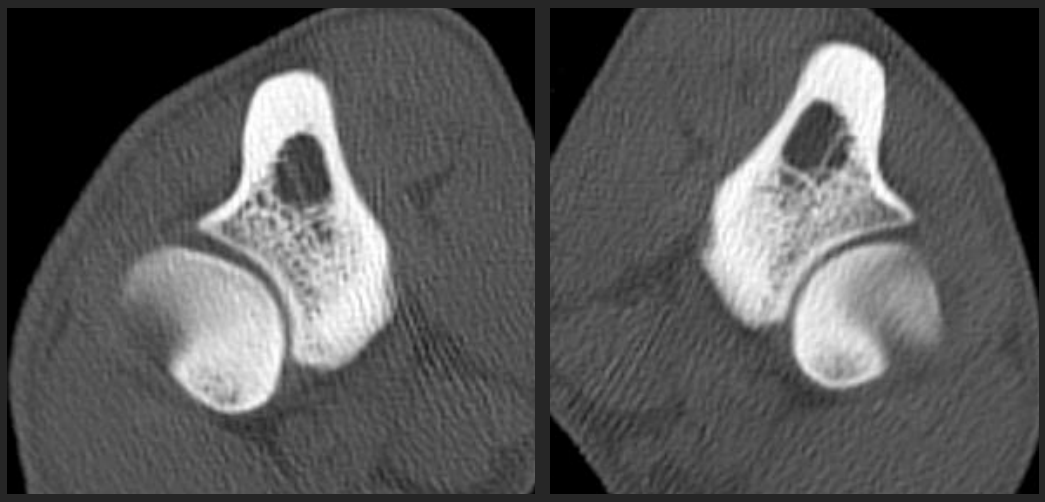

Elbow dysplasia

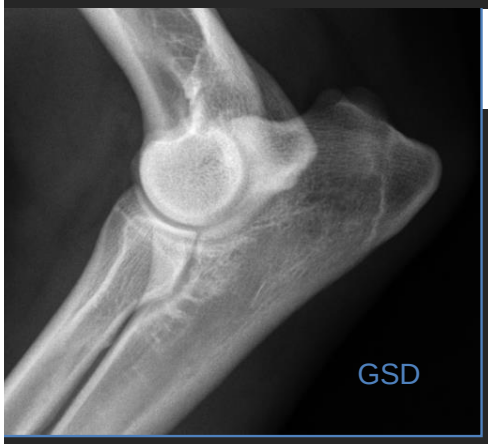

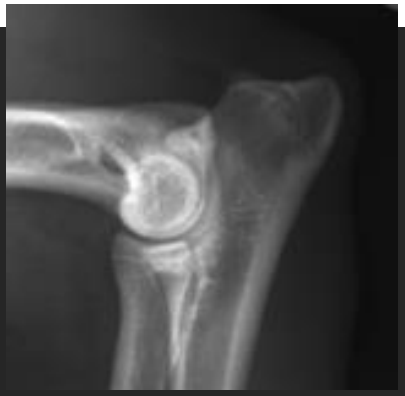

False positives?

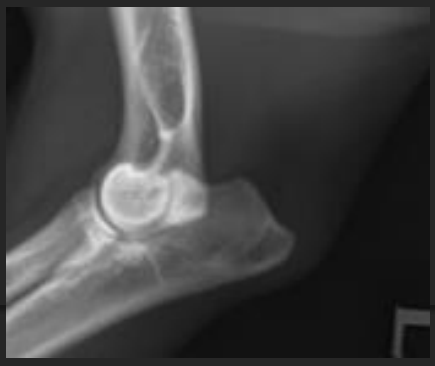

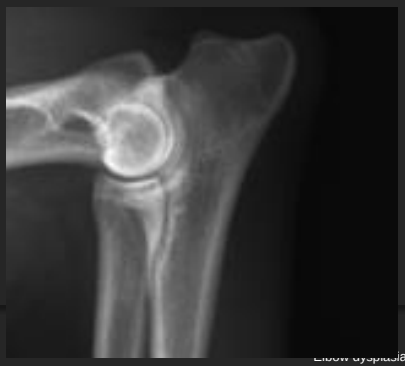

Standardized and optimized protocol

Use an existing template

- **Comparability**
- **Can be used in combination and as extension of existing schemes**

Introduce unambiguous criteria only

- **Known clinical impact**
- **Known/assumed genetic basis**

Visual decision guidance

23.06.16

Elbow dysplasia

There ARE false positive cases using x-rays…

…and false negatives…

Compared to other scoring systems:

High sensitivity of the FCI/ IEWG system for primary lesions with genetic basis

Elbow dysplasia

Elbow Dysplasia Scoring		Radiographic Findings
0	Normal elbow joint	Normal elbow joint, No evidence of incongruency, sclerosis or arthrosis
1	Mild arthrosis	Presence of osteophytes **< 2 mm high** Suspect sclerosis of the base of the coronoid processes (Step of up to 2 mm between radius and ulna) -mentioned
2	Moderate arthrosis or **suspect primary** lesion	Presence of osteophytes of **2 - 5 mm high** Obvious sclerosis of the base of the coronoid processes Step of > 2-5 mm between radius and ulna (suspect INC) Suspect presence of a primary lesion (UAP, FCP, OCD)
3	Severe arthrosis or evident primary lesion	Presence of osteophytes of **> 5 mm high** Step of > 5 mm between radius and ulna (obvious INC) Obvious presence of a primary lesion (UAP, FCP, OCD)

Elbow Dysplasia Scoring		Computed Tomographic Findings
0	Normal elbow joint	Normal elbow joint, No evidence of incongruity, sclerosis or arthrosis
1	Mild arthrosis	Presence of osteophytes **< 2 mm high** Subtrochlear sclerosis of the base of the coronoid process?? (Step of up to 2 mm between radius and ulna) -mentioned
2	Moderate arthrosis ~~or **suspect primary** lesion~~	Presence of osteophytes of **2 - 5 mm high** Obvious sclerosis of the base of the coronoid process?? Step of > 2-5 mm between radius and ulna (suspect INC) **Obvious irregularity/cystic lesions of the radioulnar incisure in combination with other findings** **2?? → 1**
3	Severe arthrosis or ~~**evident** primary lesion~~	Presence of osteophytes of **> 5 mm high** Step of > 5 mm between radius and ulna (obvious INC)

Elbow Dysplasia Scoring		Computed Tomographic Findings
0	Normal elbow joint	Normal elbow joint, No evidence of incongruity, sclerosis or arthrosis
1	Mild arthrosis	Presence of osteophytes **< 2 mm high** (Step of up to 2 mm between radius and ulna) –mentioned **Obvious irregularity/cystic lesions of the radioulnar incisure in combination with other findings**
2	Moderate arthrosis	Presence of osteophytes of **2 - 5 mm high** Step of > 2-5 mm between radius and ulna (suspect INC)
3	Severe arthrosis or primary lesion	Presence of osteophytes of **> 5 mm high** Step of > 5 mm between radius and ulna (obvious INC) Presence of a primary lesion (UAP, FCP, OCD)

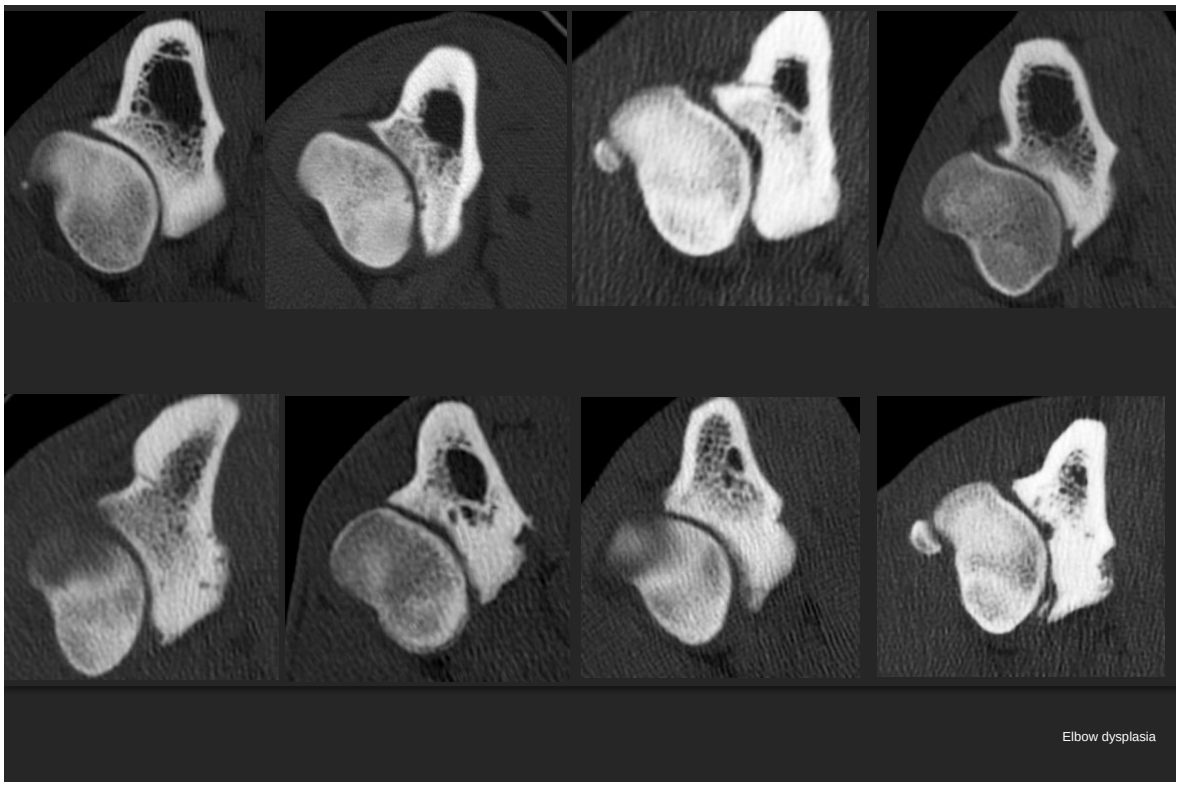

Radiography as baseline screening method

Questionable and appeal cases: CT

Open questions

- *Heritablitiy (& histopathology)*
- *Breed characteristics*
- *Observer expertise*

Elbow dysplasia

International Elbow Working Group

The International Elbow Working Group [IEWG] was founded in 1989 by a small group of canine elbow experts from the USA and Europe to provide for dissemination of elbow information and to develop a protocol for screening that would be acceptable to the international scientific community and breeders.
The annual meeting is organized for the purpose of exchanging information and reviewing the Protocol. All interested persons are invited to attend the meeting and to participate in its activities.
The IEWG is an affiliate of the WSAVA.

IEWG meetings were held in

Davis	1989
San Francisco	1990
Vienna	1991
Rome	1992
Berlin	1993
Philadelphia	1994
Konstanz	1995
Jeruzalem [cancelled]	1996
Birmingham	1997
Bologna	1998
Orlando	1999
Amsterdam	2000
Vancouver	2001
Granada	2002
Estoril	2003
Bangkok	2003
Rhodes	2004
Amsterdam	2005
Mexico	2005
Munich	2005
Prague	2006
Munich	2007
Dublin	2008
Sao Paulo	2009
Bologna	2010
Amsterdam	2011
Birmingham	2012
Cape Town	2014
Bangkok	2015
Vienna	2016

IEWG 2016

president	Herman Hazewinkel	H.A.W.Hazewinkel@uu.nl
treasurer	Bernd Tellhelm	Bernd.Tellhelm@vetmed.uni-giessen.de
secretary	Thijs How	How@wxs.nl

website**: www.vet-iewg.org/joomla**